

# Skull comparison between *Eirenis collaris* and *Dolichophis jugularis* (Serpentes: Colubridae) from Iran

Sadeghi N.<sup>a,b</sup>, Hosseinian Yousefkhani S.S.<sup>c,\*</sup>, Rastegar-Pouyani N.<sup>a,b</sup>, Rajabizadeh M.<sup>b,d,e</sup>

<sup>a</sup> Department of Biology, Faculty of Science, Razi University, Kermanshah, Iran

<sup>b</sup> Iranian Plateau Herpetology Research Group (IPHRG), Faculty of Science, Razi University, 6714967346 Kermanshah, Iran

<sup>c</sup> Department of Biology, Faculty of Science, Ferdowsi University of Mashhad, Mashhad, Iran

<sup>d</sup> Evolutionary Morphology of Vertebrates, Ghent University, Ghent, Belgium

<sup>e</sup> Department of Biodiversity, Institute of Science and High Technology and Environmental Sciences, Graduate University of Advanced Technology, Kerman, Iran

(Received: 23 April 2014; Accepted: 5 July 2014)

Two species of the family Colubridae were compared based on cranial osteology. The specimens were from Kermanshah Province (2010–2012). We compared the skulls of the two species and distinguished their differences. According to our study, eight elements of the skull are clearly different between the two species. We speculate that these differences are related to different diets, prey size, or result from evolutionary processes that adapt these species to special conditions or competition with other sympatric species. Differences and characteristics of the above species help to facilitate their identification and evaluate phylogenetic studies in relation to skull morphology.

**Key words:** Colubridae; *Eirenis collaris*; *Dolichophis jugularis*; comparative cranial osteology.

## INTRODUCTION

Skull structure shows differences among vertebrates in their diet and food habits (Herrel et al., 1999). Phylogenetically, the number of skull elements has been decreasing from amphibians to mammals (Kent and Miller, 1997). The ophidian skull is very weak and unlike the other squamates, the quadrate is more movable and the cranium is more flattened than that of Sauria (Underwood, 1967; Rage, 1984). Cranially, the colubrids have only a left carotid artery, edentulous premaxillaries, and usually longitudinally oriented maxillaries with solid or grooved teeth. The skull in colubrids is elongated and almost as broad, and all components of the cranium are ossified. The premaxilla is small and situated at the end of the snout. The septomaxillae are elongate and have a plate-like shape, providing the floor of the nasal tubes. The vomers have no teeth and are connected to the ventral surface of the septomaxillae. The frontals are well developed. The maxilla is a short and oblique shaft that is adapted to head shape. The ectoptrygoids are small, flat, stick-like bones that connect maxilla to pterygoids. The quadrates are oblong and situated in temporal region (Bullock and Tanner, 1966). Connection between quadrates and lower jaw are very important in skull movability in snakes.

Snakes are characterized by extraordinary mobility of their jaws (Gans, 1961) and with the exception of the jaw joints and fittings in the transmission of sound, no clear articulation can be seen in the

head of the snake (Rieppel, 1980; Hall, 1984). The skull in snakes is strongly modified, surangular and prearticular forming a single complex or a mixture of bones integrated during embryonic development (Bellairs and Kamal, 1981; DeBeer, 1937). The genus *Eirenis* has been revised by Mahlow et al (2013) with morphological and osteological information and they recognized 18 species in the genus. *Eirenis collaris* (Schlegel, 1837) is a species that lives in oak forests in the Zagros Mountain system under rocks and feeds on arthropods like beetles, scorpions, spiders as well as worms, and small lizards such as geckos. Usually eggs are laid at the beginning of summer and hatched during mid-summer (Weber-Séménoff, 1977). There is little information on the species' teeth, as mentioned by Mahlow et al (2013). Teeth in the maxilla increase in size posteriorly but the palatine teeth are equal in size. *Dolichophis* consists of three species (Nagy et al 2004). *Dolichophis jugularis* (Linnaeus, 1758) often lives near farmlands and feeds on rodents and is beneficial for agriculture. The species exhibits aggressive behavior in contact with humans (Amr and Disi, 2011). And also other researches confirm that *D. jugularis* feeds on rodents, frogs and sometimes birds, therefore needs to a stronger musculature system than *E. collaris* which feeds on insects, spiders, and rarely, lizards (Latifi, 1991; Rastegar Pouyani et al., 2008).

In this study the skulls of the two species of snakes have been compared morphologically and the results provide new data diagnostic of the two taxa. Cranial elements the two species of snakes (*Eirenis collaris* (Schlegel, 1837) and *Dolichophis jugularis*) have been little studied (Amr and Disi, 2011; Mahlow et al., 2013) and the present study was performed to evaluate the differences between these two colubrids to provide new osteological data for future phylogenetic studies.

#### MATERIAL AND METHODS

For the comparison three specimens from each of the two studied species were chosen (Table 1). Materials were collected from Kermanshah Province, western Iran. All the examined Adult specimens of *D. jugularis* have a maximum length = 150 cm and for *E. collaris* maximum length = 38 cm as recorded by Latifi (1991).

Skull preparation requires a clear protocol for obtaining the desired results. At first, preserved specimens were decapitated and the skin and muscles were removed by forceps and scissors, and then the heads were kept in boiling water for 10 minutes for all sizes to remove the skin from skull and then were cleaned as much as possible. After cleaning, the following protocol was employed to finalize the skull preparation:

- 1- Blood depletion by use of sodium chloride solution 5% for 12 hours.
- 2- De-fatting by use of gasoline for 12 hours.
- 3- De-coloring by use of bleaching liquid 1% for 4 hours.
- 4- Bleaching by use of hydrogen peroxide 1% for 6 hours in a dark place.
- 5- Dehydration with ethanol 96% for 24 hours.

(Skulls are immersed in liquids (alcohol, petrol and sodium chloride) at room temperature (20–25 C°).

After applying the above protocol, all skulls were marked and photos were captured by Dino-Lite digital camera. This protocol was used for *Eirenis collaris* with a thin cranium. In the case of *Dolichophis jugularis* with a thicker cranium, the protocol was changed as follows (Figs. 1 and 2).

- 1- Blood Depletion by use of sodium chloride solution 5% for 24 hours.
- 2- De-fatting by use of gasoline for 24 hours.
- 3- De-coloring by use of bleaching liquid 1% for 8 hours.
- 4- Bleaching by use of hydrogen peroxide 1% for 6 hours in a dark place
- 5- Dehydration with ethanol 96% for 24 hours.

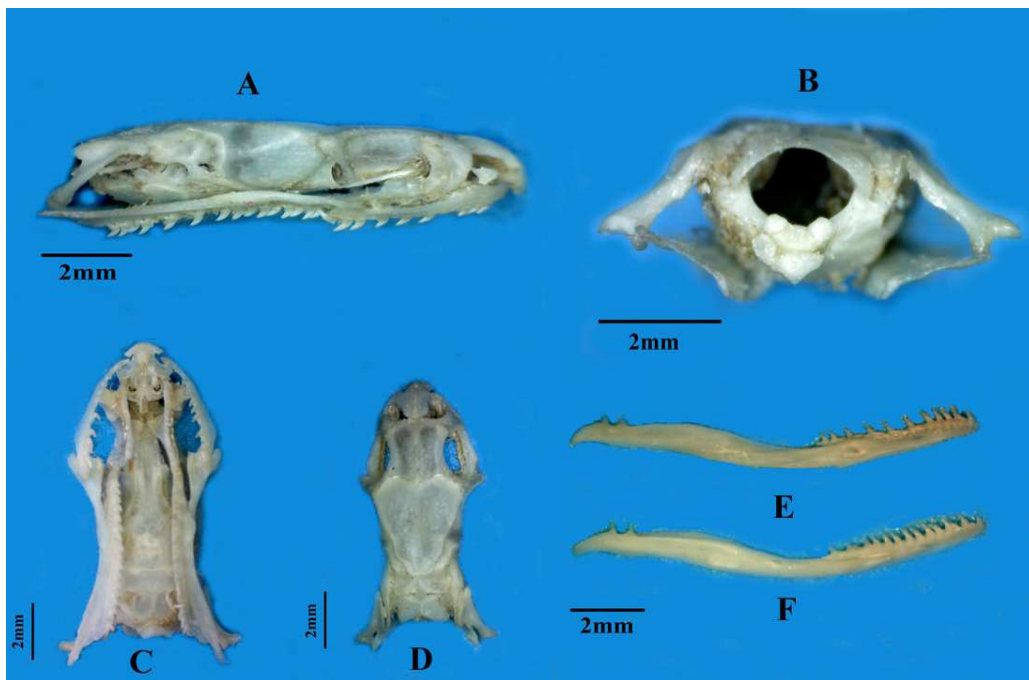
The method is optimized by several examinations in lab, because some skulls are thick and some are thin and need different methods for skull clearing (Rastegar-Pouyani and Faizi, 2007).

**TABLE 1.** Material examined in this study and some features of them.

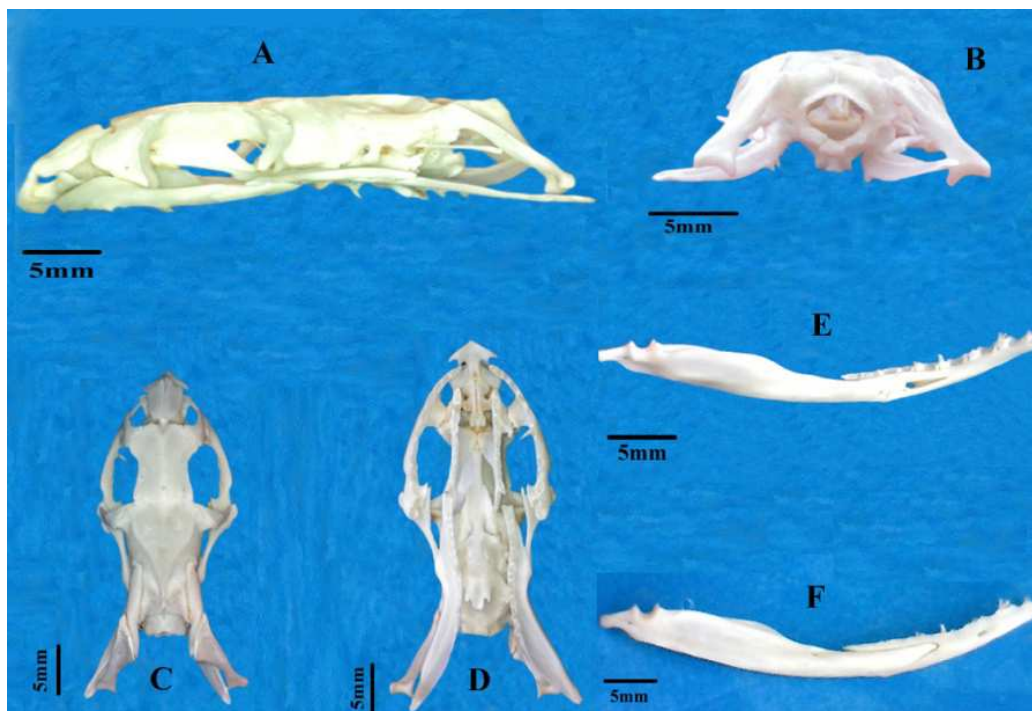
	Code	Sex	Locality	TL(mm)	SVL(mm)	VS	SCS
<i>Eirenis collaris</i>	RUZMCE10.3	Male	Kermanshah	84.29	274.45	156	62
	RUZMCE10.8	Female	Kermanshah	73.09	277.69	156	54
	RUZMCE10.31	Male	Kermanshah	45.72	159.42	147	58
<i>Dolichophis jugularis</i>	RUZMCDX.4	Female	Kermanshah	310	830	246	108
	RUZMCDX.8	Male	Kermanshah	210	600	207	81
	RUZMCDX.21	Female	Kermanshah	250	700	229	93

**TABLE 2.** Abbreviations used in the text and figures. (abb. = abbreviation).

Abb.	Bone name	Abb.	Bone name	Abb.	Bone name
A	Angular	Maf	Mandibular fossa	Ptc	Ptrygoid crest
Af	Angular foramen	Mg	Meckel's groove	Qc	Quadrato crest
Ar	Articular	Mxp	Maxillary process	Qu	Quadrato
Bo	Basioccipital	Nas	Nasal	Rap	Retroarticular process
Boc	Basioccipital crest	Np	Nasal process	Rt	Replacement teeth
Bop	Basioccipital process	Oc	Occipital crest	Sa	Surangular
Bs	Basisphenoid	Otc	Otic capsule	Sc	Sagittal crest
Chp	Choanal process	Pal	Palatine	Sf	Sigmoid foss
Cn	Compound notch	Par	Parietal	Sm.pr	Septomaxilla process
Cp	Coronoid process	Para	Parasphenoid	Sm	Septomaxilla
Cv	Cavum vomeries	pc	Parietal crest	soa	Supraoccipital area
D	Dentary	Pcp	Parotic process	Soc	Supraoccipital
Df	Dentary foramen	Pf	Parietal foramen	Sof	Supraoccipital foramen
Ec	Ectoptrygoid	Pfp	Prefrontal process	Sp	Splenial
Ecd	Exoccipital condyle	Pfr	Prefrontal	St	Stapes
Eo	Exoccipital	Pip	Posteroinferior process	Stp	Stapedial process
Ep	Ecoptrygoid process	Plp	Palatine process	Sup	Supratemporal
Era	External ramus	Pm	Premaxilla	T	Teeth
Fom	Foramen magnum	Pmch	Premaxillary channel	V2	Foramen for the maxillary branch of trigeminal nerve
Fov	Fenestra ovalis	Pmp	Premaxillary process	V3	Foramen for the mandibular branch of trigeminal nerve
Fr	Frontal	Po	Postorbital	Vf	Vomerine foramen
Ira	Internal ramus	Pr	Prootic	Vo	Vomer
Jf	Jugal foramen	Pra	Prearticular	vp	Vomerine process
Laf	Lacrimal foramen	Psp	Posterosuperior process		
Lar	Lateral arm	PspP	Parasphenoid process		
M	maxilla	Pt	pterygoid		



**FIGURE 1.** *Eirenis collaris* skull. Lateral view (A); posterior view (B); ventral view (C); dorsal view (D); dorsal view of lower jaw (E); ventral view of lower jaw (F).



**FIGURE 2.** *Dolichophis jugularis* skull. Lateral view (A); posterior view (B); dorsal view (C); ventral view (D); ventral view of lower jaw (E); dorsal view of lower jaw (F).

**RESULTS*****Eirenis collaris* (Menetries, 1832)****Snout:**

**Premaxilla (pm).** Premaxilla is a single, small bone which terminates the snout. Its anterior surface is an inverted Y-shaped ridge. Its dorsal prong is wedged between nasals. The premaxilla does not bear teeth (Fig. 3a).

**Septomaxillae (sm).** The bones that are elongate, horizontal and plate-like and form the floor of the internal nares, contact ventrally with vomers and posteriorly with frontals (Fig. 3c).

**Nasals (n).** These bones appear as an oval-shaped structure between premaxilla and the frontals. The nasals separate anteriorly and receive the dorsal process of the premaxilla, but ventro-posteriorly remain connected to form a pair of pointed processes which are connected to the anterior frontals. Dorsally the nasals don't articulate with the frontals. Also, the nasals sheath the nasal cavities dorsolaterally and form a septum that extends posteroventrally as a process which contacts the anteroventral edges of the frontals (Fig. 3b).

**Prefrontals (pf).** Left and right prefrontals are cone-shaped bones. Prefrontals dorsally articulate with antero-lateral edge of frontals and ventrally articulate with mid-mesial process of maxillae. There is a lacrimal hole on the edge near articulation with posterior sheet of maxilla (Fig. 3c).

**Vomers (vo)**

Vomers are situated posterior to premaxillary processes and beneath septomaxillae. Vomers are edentate and form a pair of spherical hollows that bear vomeronasal organs. It consists of two foramina, named vomeronasals, situated in each side of vomer cavity (Fig. 3b).

**Frontals (fr)**

The smooth and rectangular bone is located between orbits and loosely anteriolaterally articulates with prefrontals. There are two foramina in its anterior part in articulation between frontal, nasal and septomaxilla. Frontals are posteriorly articulated with parietals (Fig. 3b).

**Parietals (par)**

The parietals are fused into a single bone and are the largest elements of skull and form the posterior part of orbits. Posteriolateral edges adjoin to prootics. Ventrally, they connect to basisphenoid. The crests of parietals are V-shaped and converge towards posterior, but they don't form an angle in the articulation with supraoccipital. Posterolaterally, parietals loosely connect to postorbitals. Two tiny holes are on the posterior two thirds of this bone (Fig. 3b).

**Postorbitals (po)**

These bones are narrow, long and form the posterior border of orbit; they are flat in apical end where they articulate with anterolateral sheets of parietals, but distally they become narrow. Connective tissue connects this bone to maxilla; cleaning the skull, removed it and separated it from maxilla (Fig. 3a, b).

**Prootics (pr)**

Prootics are irregular rectangular bones. Each prootic is bordered ventrally with basisphenoid and basioccipital, posteriorly with exoccipital, dorsally with supraoccipital and anteriorly with parietal (Fig. 3c).

**Supraoccipitals (soc)**

An irregular pentagonal bone that is located posterior to parietal. From each corner two crests originate from each side, one of them extends to the end of bone and the other one shifts mid-way and in a common line, they touch each other. So, this bone forms an inverse crown shape (Fig. 3b).

**Exoccipitals (eo)**

Two exoccipitals join each other by a medial gap that constrains posterolateral walls and roof of braincase. This bone connects supraoccipital and prootic anteriorly and basioccipital ventrally. In lateral view, there is an enlarged jugular foramen on this bone that is exactly posterior of fenestra

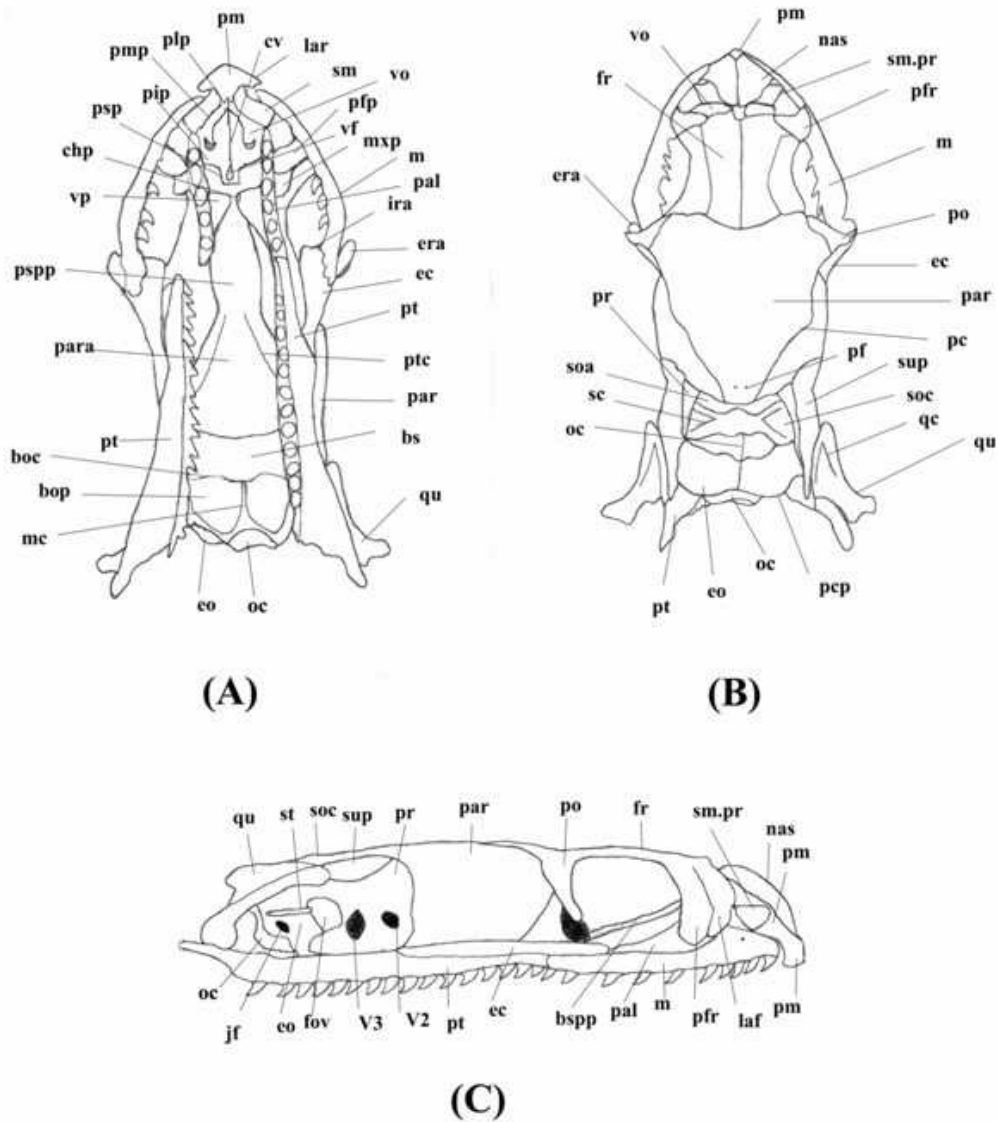


FIGURE 3. Skull of *Eirenis collaris*; A) ventral, B) dorsal, C) lateral view.

ovalis. Exoccipitals, posteriorly form the foramen magnum, barring a part of occipital condyle (Fig. 3a, b).

**Basioccipital (bo).** Basioccipital is a pentagonal bone located between occipital condyle and basisphenoid, posteriorly bordered by exoccipital and anteriorly connects with basisphenoid; the crests of upper edges traverse the mid-line and join each other in the middle and form the middle crest; this ventral nodule finally constitutes the ventral part of occipital condyle (Fig. 5a).

**Parabasisphenoid (pbas)**

Basiparasphenoid consists of two parts, parasphenoid that is a narrow and almost oblong oval shaped bone and basisphenoid is a polyhedral and smooth bone. This compound bone is laterally and dorsally bordered with parietals and prootics. From posterior, it articulates with basioccipital.

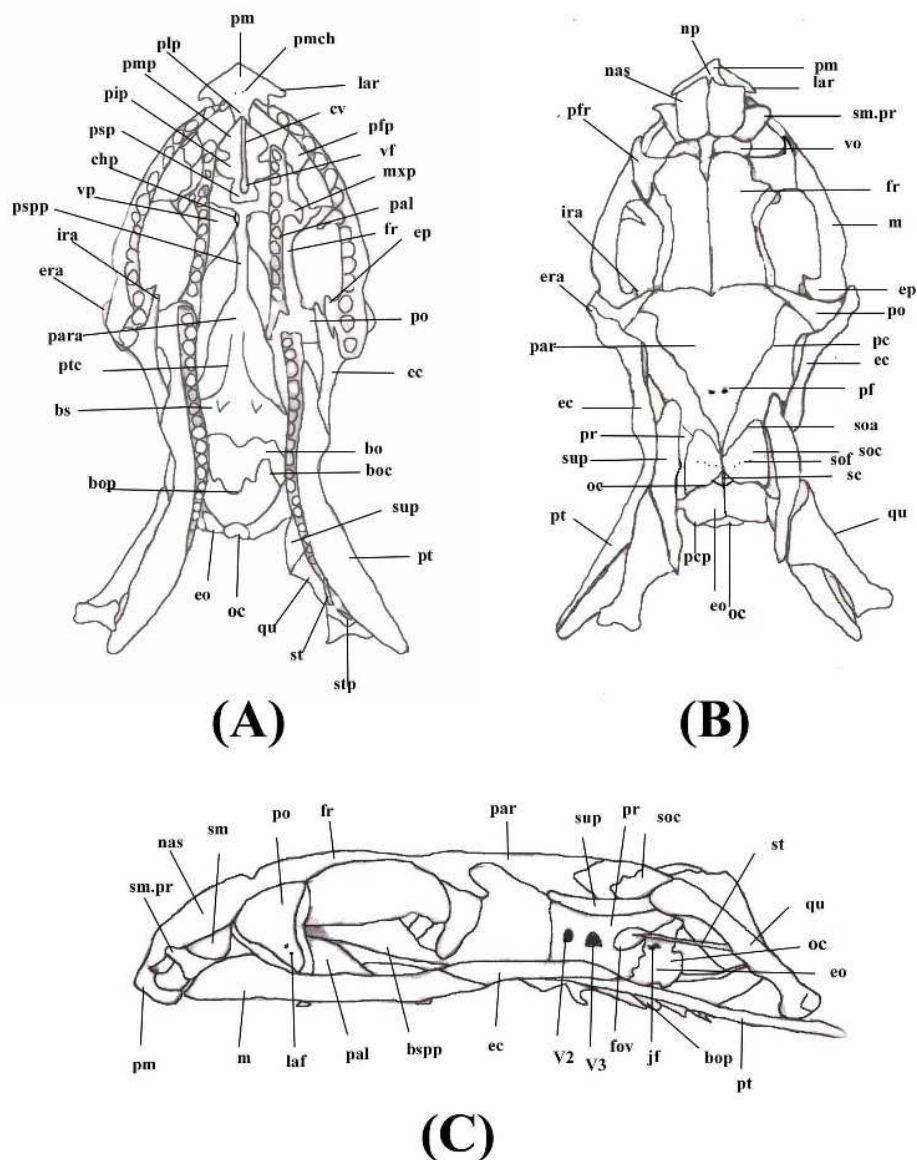


FIGURE 4. Skull of *Dolichophis jugularis*; A) ventral, B) dorsal, C) lateral view.

#### Palatamaxillary Arch:

**Palatines (pal).** Each palatine is a short and curved bone having 9-10 teeth. The posterior end of it, articulates with anterior end of pterygoid. In the middle of the bone, each palatine has a middle flat process, the vomerine process that is curved inward. Another process, the maxillary process, articulates with ventral edge of prefrontal. Palatines connect to snout with connective tissue (Fig. 3a).

**Pterygoids (pt).** These bones are flat bars that like palatine are located medially before forming articulation with ectopterygoid,. Each pterygoid at the loose articulation with palatine is narrow, and then it extends posterolaterally to the corner of jaw. Each palatine bears 15 or 18 teeth. From articulation with palatine to end of teeth row, this bone is straight, then it curves to the corner of jaw (Fig. 3a, c).



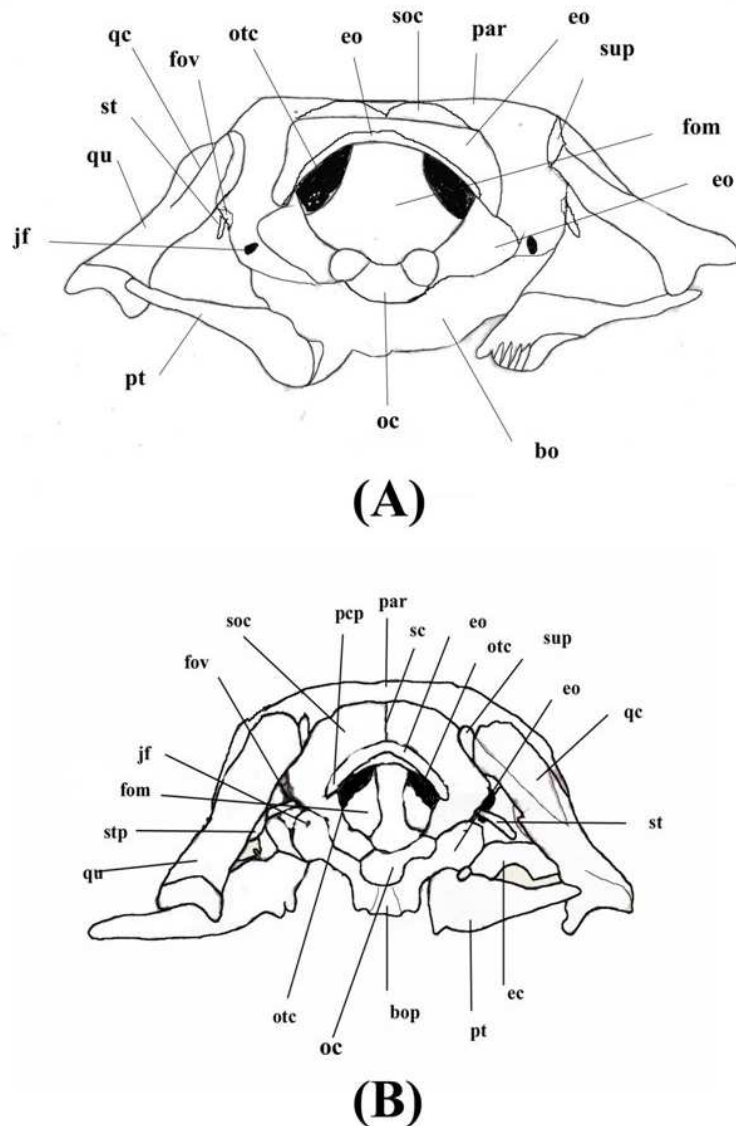


FIGURE 5. posterior view of the skull. A) *Eirenis collaris* and B) *Dolichophis jugularis*.

**Ectopterygoid (ec).** Ectopterygoids are almost Y-shaped bones that form a connective bridge between maxillae and pterygoids. They have three rami; of the two anterior rami, the internal ramus is sharp, while external ramus is flat. The posterior ramus is elongated. Ectopterygoids don't have any teeth (Fig. 3a, c).

**Maxillae (m).** Left and right maxillae are short and curve-shaped. On the mid-mesial surface of each maxilla there is a small process that articulates with the ventral surface of the prefrontal. The posterior ends of the maxillae are broadened and are received by the flattened club-shaped ventral surface of the ectopterygoids. Each maxilla includes about fifteen or sixteen curved, equal size teeth. The maxillae are connected by fibrous tissue to the premaxillae and not articulated as in most vertebrates (Fig. 3a, c).



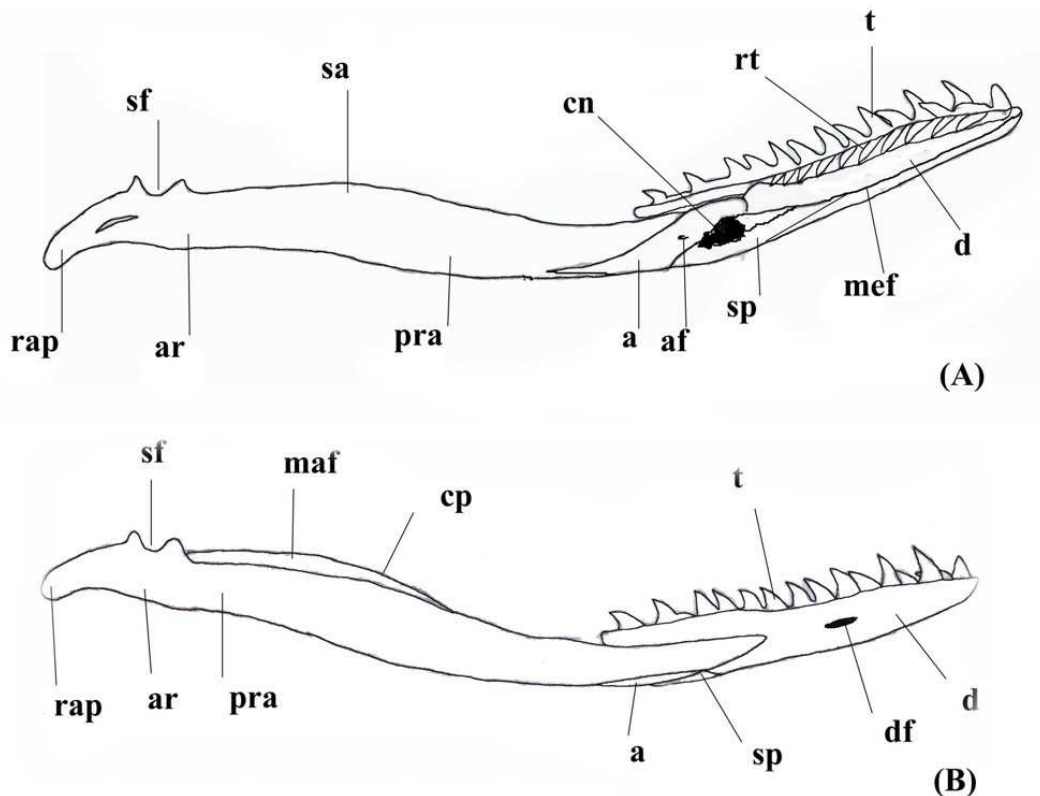


FIGURE 6. Mandible of *Eirenis collaris*; A) internal and B) external views.

### Mandibular Unit

#### Supratemporals (sup)

Each supratemporal, is a flat, narrow bone that is located on the posterior skull with intermediate connection of quadrate to neurocranium. This bone is connected loosely to parietal, supraoccipital, and prootic.

#### Quadrate (qu)

Each quadrate is almost flat and triangle-shaped. It articulates posterolaterally with supratemporals and ventrally with lower jaw. In the middle of each quadrate, there is a stapedial process that articulates with terminal side of stapes.

#### Stapes (st)

Stapes are slender, narrow bones that connect between otic capsule and quadrate. It connects to oval shaped process in the middle of quadrate, the stapedial process by fenestra ovalis.

**Mandible:** the Mandible is composed of two jaw bones, compound bone and dentary.

The compound bone

Each compound bone is composed of 5 toothless parts, angular, splenial, surangular, prearticular and articular. The two bones, prearticular and articular form the condyle of jaw. Articular is vertically elongated and forms two nodules so that an S-shaped groove is created between two nodules. Angular is a triangular bone, located under prearticular and articulates with splenial laterally. There is a foramen inside. Splenial is a thin and triangular bone that is connected laterally to angular and dentary. It is smallest bone in compound bone. Prearticular is moderately slender bone that forms the greater part of compound bone and located in elongation of articular (Fig. 6a, b).

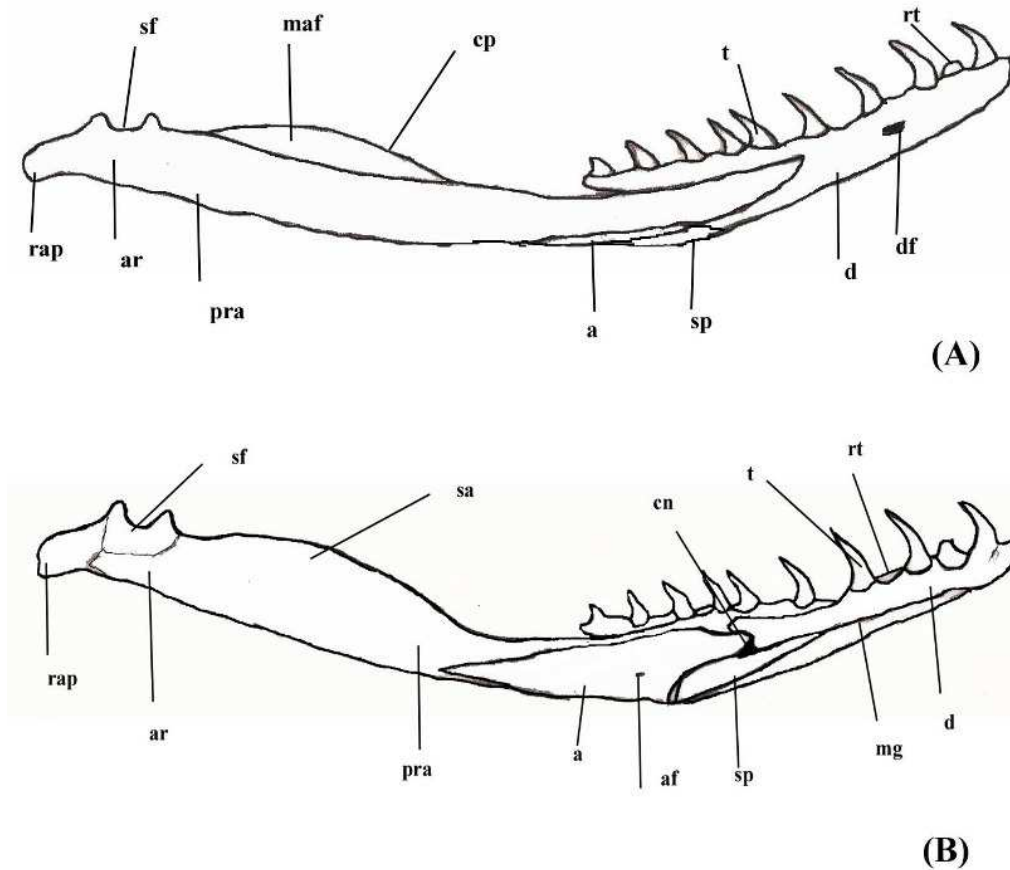


FIGURE 7. Mandible of *Dolichophis jugularis*; A) lingual and B) labial views.

### Dentary

Each dentary constitutes anterolateral part of jaw and has 16 or 18 teeth. The tip of it is somewhat thin. It has a groove, Meckel's groove, in the middle of ventral surface. There is a foramen in the dorsal surface of dentary.

### *Dolichophis jugularis*

#### Snout:

**Premaxilla (pm).** The bone forms the front angle of the upper jaw. The bone has four lateral arms and its tip is sharp. It has no teeth (Fig. 4a, b, c).

**Septomaxillae (sm).** Septomaxillae are located behind the premaxillae and contact maxillae from the upper side. The bone is located in front of the nasal capsule (Fig. 4a, b, c).

**Nasals (n).** Nasal bones are the bones that form most of the roof of the skull, being followed in sequence by the frontals, parietals, and postparietals. Nasals contact the frontal posteriorly (Fig. 4b).

**Prefrontals (pf).** Prefrontal is a triangular bone situated on each side between the frontal bone and the maxilla and not in contact with nasals. The bone located at the anterior corner of orbit (Fig. 4b).

**Vomers (vo).** Vomers are located at the roof of buccal cavity and are narrow and connected to the ventral surface of septomaxillae and with this structure they form a hollow for the vomeronasal organ in buccal cavity. They reach each other anteriorly and each of them reaches to the parasphenoid process posteriorly (Fig. 4b).

**Frontals (fr).** Frontal is the long bone on top of the skull, situated between the parietal posteriorly and nasals anteriorly. Frontal contacts the prefrontals anterolaterally. Dorsal surface of each frontal is flat and there is a groove in each parallel with the orbital edge (Fig. 4b, c).

**Parietal (par).** Parietal is the largest bone in skull and is situated posterior to the frontals anteriorly. The bone contacts the postorbitals anterolaterally. The posterior crest of the bone creates a sharp tip in contact with supraoccipitals posteriorly (Fig. 4b, c).

**Postorbitals (po).** Postorbital is a small and elongated flattened bone which articulates with anterolateral surface of the parietal and forms the dorsal boundary of each orbit and is a connection between postorbital and ectopterygoid (Fig. 4a, b).

**Prootics (pr).** The bone is irregular and square-shaped and has four processes. It articulates with the basioccipital ventroposteriorly, with the supraoccipital dorsally, with the basisphenoid ventrally and with the exoccipital ventrolaterally. The lateral margin of the prootics between the trigeminal foramen and fenestra ovalis is grooved. The crista prootica includes a ventrally deflected lip that is confluent with the arc of the opisthotic crista interfenestralis and short relative to the condition in other taxa (e.g., booids, pythonids, many colubroids), indicating that the stapedial footplate would be mostly exposed in lateral view (Fig. 4c).

**Supraoccipital (soc).** Supraoccipital is anteroposteriorly short and the bone has a triangular apex that articulates with the parietal. It forms the dorsal rim of the foramen magnum and posterolaterally joined with the exoccipital (Fig. 4c).

#### **Exoccipitals (eo)**

These two bones constitute roof of braincase and foramen magnum and articulate anteriorly to prootic and supraoccipital and connect to basioccipital ventrally. The jugular foramen situated exactly posterior to fenestra ovalis (Fig. 4a, b).

**Basioccipital (bo).** Basioccipital is pentagonal-shaped and its ventral surface has a low, sagittal ridge with a laterally depressed area on either side. Posterior part of the basioccipital forms the ventral portion of the occipital condyle. Basioccipital is bordered laterally by the exoccipitals and is joined anteroventrally with the basisphenoid (Fig. 4a).

**Parabasisphenoid (pbas).** The parabasisphenoid can be seen in ventral view and located at the roof of skull. The bone is diamond-shaped and includes two processes. Basioccipital process is located at the posterior side of the bone and has two processes with parasphenoid anterolaterally. Pterygoid crest is very sharp in this species on parabasisphenoid bone.

#### **Palatomaxillary Arch:**

**Palatines (pal).** Palatine makes contact in three regions with vomers anteriorly, pterygoids posteriorly and the maxilla posterolaterally. The posterior end of each palatine articulates with the anterior end of the pterygoid. The palatines are connected by fibrous connective tissue to the snout components (Fig. 4b, c).

**Pterygoids (pt).** Pterygoids are long and parallel to the axis of the skull. The pterygoid is connected with the maxillary by the ectopterygoid and the maxillary extends a process towards the palatines. Anteriorly it narrows and forms a loose articulation with the posterior end of the palatine. The pterygoid receives the ectopterygoid into a dorsolateral groove. From the palatine articulation there are eight to twelve teeth (Fig. 4c).

**Ectopterygoids (ec).** Ectopterygoids are small and club-shaped flat bones connecting the maxillae to the pterygoid (Fig. 4a, c).

**Maxillae (m).** Maxilla forms the upper jaw of snakes and is usually tooth-bearing. These bones are separated at the front of the jaw by premaxilla bones. Lacrimal foramina are situated in upper side of the maxilla. Maxilla contacts septomaxilla from the upper frontal region.

**Mandibullar Unit:**

**Supratemporals (sup).** A small bone that articulates with quadrate at the posterior of skull. The bone is in contact laterally with pterygoid.

**Quadrates (qu).** The quadrate bone is elongate and very mobile and occupies a posterolateral position. The bone articulates with the pterygoid ventrally and with the supraoccipital dorsally.

**Stapes (st)**

Each bone is slender rod-shaped and is a connector between the quadrate bone and otic capsule. It is supposed to transmit the sound variation from lower jaw to otic capsule.

**Mandible:** Mandible is composed of two jaw bones, compound bone and dentary

**Dentary.** The bone is narrow and elongate bears 16–18 teeth. Meckel's groove is located on the medial side. Dentary articulated with the coronoid posterodorsally and with the angular posteriorly. In lateral view the dentary foramen can be seen in anterior part of the dentary and dentary articulates with splenial ventrally. In this snake, the lower lip of dentary is shelf-like.

**Compound bone.** The bone consists of five bones as follows: angular, splenial, surangular, prearticular and articular. Surangular is strongly developed, so that it creates a more prominent articular condyle.

**COMPARISON**

**Premaxilla:** Premaxilla is small and connected to the end of the snout in *Eirenis collaris*; in contrast, four lateral arms in *Dolichophis jugularis* are better developed than those of *Eirenis collaris*. Tip of the Premaxilla in *Eirenis collaris* is flattened but in *Dolichophis jugularis* is pointed (Fig. 4A).

**Nasals:** Nasals included are two bones that form the joint between them and are located between premaxilla and frontal. Nasals in *E. collaris* are like a butterfly's wing, while lateral edges of the bone are less extensive in *D. jugularis* and almost created a cup-shaped process (Figures 3, 4 B).

**Prefrontals:** Effects of lacrimal bone-like hole situated on this bone. In the lateral view, one anterior appendage is observed that is compressed laterally, but this appendage is drawn more towards the front and is smaller in *E. collaris* than *D. jugularis*. The bone in lateral view looks triangular (Figs. 3,4 B).

**Frontals:** These bones are located between parietal and nasal and have weak connection via connective tissue. All features of the bone are similar between the two species but have some differences in lateral sides. Owing to the fact that in *D. jugularis*, orbit is larger than whole cranium, the curvature is greater (Figs. 3,4 B).

**Parietals:** The largest bone that is located behind the frontal. The line connecting in *E. collaris* has the curvature larger than *D. jugularis*. The ridges of the bone that were converging towards each other, created a sharp angle at the junction with the supraoccipital (Figs. 3, 4 B).

**Basioccipital:** The bone is five-sided and situated under the basisphenoid bone. In *E. collaris* the bone is clearly distinguished whereas the middle crest is not clearly distinguished in *D. jugularis*. Crests in this bone are well directed upward and converted to an appendix in *D. jugularis*. This appendix has three lobes with the middle lobe, which is larger than the lateral lobes. (Figs. 3, 4A).

**Supraoccipital:** The bone is butterfly-like and is very different from the corresponding bone in *E. collaris*. Occipital crest well developed, whereas this crest is very clear in lateral view in *D. jugularis* (Figs. 3, 4B; Figs. 5 A, B).

**Palatines:** These bones are short and connect with pterygoids. Palatines have a distinct part as maxillary that is different between two species. The bone is horizontal with direct tip in *E. collaris*, but in *D. jugularis* shows a distinct overhang (Figs. 3, 4A).

**Mandible:** Mandible consists of compound bone and dentary system. Compound bone is composed of five parts, for example angular, splenial, surangular, prearticular and articular. Surangular bone in *D. jugularis* better developed than in *E. collaris* and creates a distinct condyle. Articular is slightly curved down in *D. jugularis*, also prearticular bone has a steeper gradient than similar bone in *E. collaris* (Figs. 6, 7).

**Dentary:** This bone is narrow and elongated and contains about 16 to 18 teeth. The bone in most features is similar to *E. collaris* but has some differences. The bone in *D. jugularis* has a smaller hybrid gap and the lower edge has a steeper gradient.

## DISCUSSION

*Eirenis collaris* and *Dolichophis jugularis* belong to two separate genera, so that one can expect differences in their crania. In this study clear differences have been shown between these two species. Differences in skull morphology may suggest that diet is different between them, because *D. jugularis* has a large body and also has a large head, and the species may eat large prey, such as mice and birds (Amr and Disi, 2011). Also this difference can have resulted from phylogenetic factors because use of different food sources affect the skull shape and changes shape of several bones especially mandibul and its joint with the skull to facilitate feeding, especially between small and large prey (Mahlow et al., 2013).

Supraoccipital bone is expanded in *D. jugularis* creating wide crests, but in *E. collaris* that is narrow and created some apexes on this bone. Premaxillas have the flatted tip with undeveloped arms in *E. collaris* differing from *D. jugularis* with developed arms and the sharp apex.

*Dolichophis jugularis* has convergent crests in its parietal creating a steep angle at the joint with supraoccipital, while in *E. collaris* the crests do not meet and create a steep angle with supraoccipital. In the ventral view of skull, the obvious differences between the two species are related to the basiparasphenoid bone and in *E. collaris* parasphenoid appendix is oval and basisphenoid is flat and smooth and the pterygoids are unclear, but in *D. jugularis* the parasphenoid is narrow, basisphenoid has the rectangular shape and the pterygoids are clear and sharp. The vomer is the other bone that differs between the two species. The vomer situated at the ventral side of the skull and under the premaxilla has three appendices that differ in the two species. The bone has several holes in its length in *D. jugularis* but in *E. collaris* is closed and exactly at the end the opening appears as a hole. The postorbital, prootic, quadrate, supratemporal, exoccipital and stapes are the bones that are similar in these two species.

The lateral sides of nasal have little expansion in *D. jugularis* creating a cup-shaped form, but in *E. collaris* they make butterfly appendices. In compound bones, surangular bone in *D. jugularis* is more expanded than in *E. collaris* and forms the more prominent condyle. In *D. jugularis* the articular appendix has a curvature that is smaller in bottom than that of *E. collaris*, and also the periarticular has the steeper slope in *D. jugularis* than *E. collaris*. Finally, the dentary in *D. jugularis* has a smaller compound notch and the lower lip of this bone has steeper slope than *E. collaris*.

## ACKNOWLEDGMENTS

We thank Kazem Hatami for special cooperation with taking the photos. Our special thanks go out to Prof. Steven C. Anderson for useful comments on an earlier draft of the manuscript.

## LITERATURE CITED

Bellairs, A.A., Kamal, A.M. 1981. *The chondrocranium and the development of the skull in recent reptiles*, In *Biology of Reptilia*, vol.11, C.Gans and T.S. Parsons, eds.London: Academic Press, 263 pp.

- Bullock, R.E., Tanner, W.W. 1966. Comparative osteological study of two species of Colubridae (*Pituophis* and *Thamnophis*). *Brigham Young University Science Bulletin*, 8, 1 – 29.
- De Beer, G.R. 1937. *The Development of the Vertebrate Skull*, Oxford Univ. Press, London.
- Gans C. (1961), "The feeding mechanism of snakes and its possible evolution," *American Zoology*, 1, 217 – 227.
- Hall, B.K. 1984. Matrices control the differentiation of cartilage and bone, In *Matrices and Cell Differentiation* (ed. R. B. Kemp & J. R. Hinchliffe), pp. 147–169. New York: Alan R. Liss Ink.
- Herrel, A., Peter, A., Jeannine, F., Frits, D. 1999. Morphology of the feeding system in agamid lizards, ecological correlates, *The Anatomical Record*, 254, 496 – 507.
- Kent, G.C., Miller, L. 1997. *Comparative Anatomy of the Vertebrates*, 8th ed. Wm. C. Brown Publishers, Dubuque. 487 pages. ISBN 0-697-24378-8.
- Latifi, M. 1991. *The Snakes of Iran*, Contrib. Herpetol. Vol. 7, Soc. for the Study of Amphibians and Reptiles, Athens (Ohio, USA).
- Rage, J.C. 1984. *Serpentes*, Handbuch der Paläoherpetologie Teil 11. Gustav Fischer Verlag, Stuttgart – New York, 80 pp.
- Rastegar-Pouyani, N., Faizi, H. 2007. Geographic variation in the skull morphology of *Trachylepis aurata transcaucasica* Chernov, 1926 (Sauria: Scincidae) in the Zagros Mountains, Western Iran. *Zoology in the Middle East*, 42, 67– 74.
- Rastegar-Pouyani, N., Kami, H.G., Rajabizadeh, M., Shafiei, S., Anderson, S.C. 2008. Annotated checklist of amphibians and reptiles of Iran. *Iranian Journal of Animal Biosystematic*, 4, 43 – 66.
- Rieppel, O. 1980. The sound-transmitting apparatus in primitive snakes and its phylogenetic significance. *Zoomorphology*, 96, 45 – 62.
- Underwood, G. 1967. A contribution to the classification of snakes, Publ. Brit. Mus. (Nat. His.), 179 pp.
- Vitt, L.J., Caldwell, J.P. 2009. *Herpetology*, Academic Press is an imprint of Elsevier, 3<sup>rd</sup> edition, 697 pp.
- Young, J.Z. 1981. *The Life of Vertebrates*, Third Edition. Clarendon Press, Oxford, 645 pp.